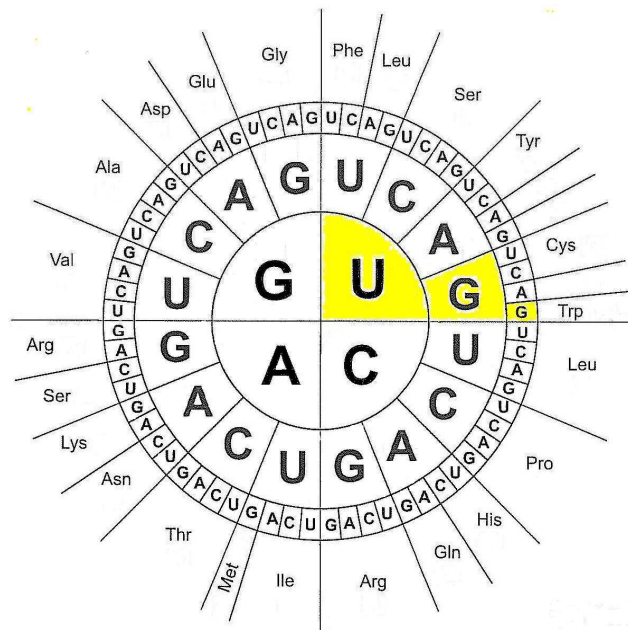


Treatment with biologically active ribonucleic acids (RNA) (formerly REGENERESIN)

Many years of treatment experience in a
naturopathy practice



Author:
Dr. Hans-Joachim Weiler
Doctor of naturopathy

Image on the title page:
the genetic code shown as a code table.

Transfer RNA contains a section with three characteristic bases which determine which amino acid binds to it and is used for protein synthesis. Corresponding to the specific three bases on the transfer RNA, there are also three bases on the messenger RNA, in other words the RNA strand which carries the information to form a complete proteins. The graphic shows the possible sequence of bases on the messenger RNA with the corresponding amino acids. This graphic is read from inside to outside. If, for example, the messenger RNA has the bases uracil, guanine, guanine (UGG) in this order, a transfer RNA will bind to this site which carries the amino acid tryptophan (trp). In this way, the genetic code determines the sequence of amino acids in each protein.

The genetic code is used in this form by almost all living creatures.

Dr. Hans-Joachim Weiler
Doctor of Naturopathy
Riedsteige 14
D-72280 Dornstetten

First edition, June 2013


Foreword

During my many years of collaboration with Dr. Weiler, we came up with the idea of publishing his experiences of Regeneresen (RNA) therapies in a compact form. We started this project at the beginning of this year, and now we have produced this brochure along with general information and personal experiences. Since Dyckerhoff Pharma is celebrating its 50th anniversary this year, you are also getting a kind of "anniversary brochure"!

We hope that this brochure provides you with useful tips for treatment in your practice, as this is what it was conceived for.

We would like to thank Dr. Weiler for this brochure and look forward to continuing to work with him in the future.

Cologne, June 2013



ppa. Dr. Georg Stommel
Dyckerhoff Pharma GmbH & Co. KG

Introduction

This brochure contains both standard knowledge about treatment with biologically active ribonucleic acids and reports of experiences from my many years as a Doctor of Naturopathy. The selection of examples is intended to demonstrate the breadth of possible uses and give tips on how treatment plans can be individually implemented for each patient.

In Cologne well over fifty years ago, Professor Dyckerhoff developed a treatment concept for the regenerative treatment of chronic and degenerative diseases. He isolated ribonucleic acid from the somatic cells of cows and produced purified sterilised ampoules from this, which he called RNA therapy.

The sterilisation of the final medication and the removal of proteins means that no transfer of infectious material e.g. BSE is possible with this treatment. The manufacturing process is also scientifically proven (validated).

It has been proven that starting from the age of 40, the body lacks sufficient ribonucleic acids of its own for biological reasons. But ribonucleic acids are essential to the healthy functioning of all cells in the body. Healthy cell function is essential to the body's ability to regenerate. It can make a diseased organ or tissue healthy again and prevent a disease from becoming chronic or degenerative changes (wear and tear) from occurring.

Biologically active ribonucleic acids work on an organ-specific basis, balance out deficiencies at the location of the disease and strengthen the immune system, in other words the body's own defences, so naturopathy therapists can set the regeneration process in motion in damaged organs or organ systems.

About me

I was born in Weimer, Thuringia in 1943. By the time I retired in 2010, I had worked as a doctor for almost 45 years. From 1991 to 2010, I worked in a private clinic in Freudenstadt in the Black Forest.

During this time I undertook extensive training in classical naturopathy methods. I focused in particular on manual therapy, neural therapy/pain therapy, infusion therapy, colonic irrigation and complex homeopathy.

In 1995, I started the company Dyckerhoff in Cologne using the REGENERESSEN treatment. I was convinced by the logical treatment approach and the simple applicability of the Regeneresen therapy in various clinical pictures. The treatment successes achieved with this treatment in my practice were so outstanding that I was able to and am able to give a large number of practical seminars for other therapists. In September 2010 I was able to hand my practice over to an experience doctor of naturopathy, with the reassuring knowledge that he would continue my proven treatment concept in addition to his own therapies to the benefit of the patients.

I myself did not entirely stop when I retired. Through patients, I was made aware of the Paracelsus Al Ronc Clinic in Castaneda in the canton of Graubünden in Switzerland. This clinic has consistently been working on naturopathy methods. Many patients in this clinic showed similar clinical pictures to those I had observed in my own practice. At the start of 2012, I was integrated into the team of therapists in this clinic and worked there temporarily.

Information on treatment with Dyckerhoff extracts:

There are regenerating Dyckerhoff extracts for 50 different organs of the body and organ systems.

Choroid membrane	Cerebellum	Osteoblast
Artery	Bone marrow	Ovary
Eye	Cartilage	Pancreas
Intervertebral discs	Liver	Placenta
Connective tissue	Lung	Prostate
Large intestine	Lymph nodes	Retina
Small intestine	Stomach	Spinal cord
Pineal body	Medulla oblongata	Thyroid gland
Vascular wall	Spleen	Basal ganglia
Cerebral hemispheres	Midbrain	Synovia
Cerebral cortex	Muscles	Testes
Urinary bladder	Adrenal gland	Thalamus
Skin	Adrenal medulla	Thymus
Heart	Adrenal cortex	Vertebra
Auditory system	Parathyroid gland	Diencephalon
Hypophysis	Optic nerve	
Hypothalamus	Kidneys	

Special recipes

RN 13 (Mixture of: vascular wall, cerebral cortex, heart, hypophysis, hypothalamus, liver, spleen, adrenal cortex, kidneys, ovary, placenta, testes, thalamus and Na-RNA from yeast)

Osteochondrin S (Mixture of: intervertebral discs, cartilage, synovia, placenta, Na-RNA from yeast)

AU 4 (Mixture of: auditory system made up of the auditory pathway, auditory nerve, auditory cortex, inner ear and Na-RNA from yeast)

Otology (Mixture of: auditory system, vascular wall, placenta and Na-RNA from yeast)

Treatment of this kind is possible immediately, also as an additional treatment, primarily when other treatments do not achieve a long-term improvement or for patients who have "had enough" of conventional medicine.

Experienced therapists have been able to collect the best experiences in their practices over a number of years using Professor Dyckhoff's regeneration therapy. Even though in some cases the patient cannot be completely healed, these patients are still very happy about the considerable improvement in their symptoms or at least an improvement in the condition and therefore an increased quality of life. It generally takes 4-6 weeks after the end of a series of treatment for the therapy to fully take effect and the patient to feel an improvement in his or her condition.

The Dyckerhoff extracts are injected into the muscles or administered as an infusion. For really effective treatment, a total of around 12-18 vials are necessary, administered over a period of 2-4 weeks. The number of vials used depends on the type of disease, the severity and the age of the patient. Even children and young people with certain diseases can be successfully treated with Dyckerhoff extracts during this time. Repeated treatments at an interval of 6-12 months are recommended.

For all Dyckerhoff extracts, the only **contraindication** manifest gout, as the active ingredients are converted into the metabolic product uric acid.

Interactions with certain antibiotics such as tetracycline, chloramphenicol and aminoglycoside antibiotics are possible. If treatment with antibiotics becomes necessary during the treatment series with Dyckerhoff extracts, this should be suspended until the end of treatment with antibiotics.

The only known **side effects of treatment with Dyckerhoff extracts** are hypersensitivity reactions (e.g. reddening of the skin, itching). They only occur very rarely (< 1 in 10000). In this case, treatment should be ceased.

What do biologically active, regenerating Dyckerhoff extracts help with?

- disorders of general wellbeing (e.g. general weakness, poor performance, burn-out as a result of excessive professional or mental demands, age-related breakdown processes)
- disorders or diseases of the hormone system (e.g. diabetes mellitus, thyroid diseases). Both hyperfunction and hypofunction can be successfully treated.
- disorders of the immune system (e.g. susceptibility to infection, lack of thymus peptides).
- diseases of the spine and the joints (e.g. arthrosis, osteoporosis, intervertebral disc damage, chronic pain syndromes of the musculoskeletal system and rheumatic diseases).
- diseases of the nervous system (e.g. multiple sclerosis, Parkinson's disease), the sensory organs (e.g. hardness of hearing, tinnitus, acute hearing loss, macular degeneration)
- diseases of the vascular system (e.g. arteriosclerosis).
- diseases of the internal organs (e.g. heart, lungs, stomach, intestine, liver, kidneys etc.).

However, an experienced therapist will develop a treatment concept using Dyckerhoff extracts and the selection of organ types on a very individual basis, as in many cases, particularly in older patients, there can be various different clinical pictures in which several organs in the organ systems are involved. This is known as multi-morbidity.

Intramuscular injection or infusion?

In 1995 I was already using Regeneresen therapy as infusion therapy in addition to intramuscular injections which were permitted at that point within the scope of my freedom to choose treatments. On the basis of the experiences of other therapists, I decided to use the ribonucleic acids intravenously for a number of reasons: several of my patients had been prescribed Marcumar for various reasons. With this medication, most patients who were still multi-morbid could of course not have an intramuscular injection. I saw particularly good Regeneresen therapy results in precisely this group of patients, though, which is why I made the decision to administer the treatment intravenously. In most cases, I was more than correct about the success. I always gave intramuscular injections to patients who were being treated with aspirin.

Another reason for intravenous use was cachetic patients who did not have enough muscle for an intramuscular injection of 20-30 ampoules.

The intravenous approach was also taken in patients with considerable disruptions to their peripheral circulation, despite the fact that in these patients the full uptake of these highly valuable medications in the blood stream is not certain to be achieved.

For Regeneresen infusion therapy, I always used 250ml of physiological saline solution, and generally gave 5-7 ampoules of Regeneresen therapy in each infusion. I always administered these infusions once a week, in exceptional cases twice a week. In principle, no other medications are added. This also applied to the intramuscular injections. I developed each treatment plan individually (depending on the clinical picture) together with the patient. The costs of treatment were also explained to him or her before the start of treatment. This meant that I never had problems with payments although the statutory and later private health insurance providers did not or only very rarely contributed to the costs.

In no cases did I observe any complications or undesired side effects with either intramuscular or intravenous administration of the Regeneresen therapy.

In the period from 2000 to 2010 (it is not possible to determine the figures before this because of the change in treatment programme), I carried out at least 300 series of treatments. These series of treatments

were mainly intramuscular in the gluteus maximus muscle. Where there was a high level of success with the initial treatment series, many patients repeated the Regeneresen therapies at intervals for further stabilisation. Twenty to forty ampoules of Regeneresen were generally used for each series of treatment.

Over the same period, I administered at least 50 infusion series with Regeneresen, with around 30-50 ampoules per series.

This method is clearly visible in the treatment cases attached.

As part of my stay at the Paracelsus Al Ronc Clinic in Castaneda, I passed on my many years of experience in pain and Regeneresen to the patients and the medical staff. Under the guidance of lead physician in the clinic Dr. Petra Wiechel, the team of therapists carried out the infusion therapy with the Dyckerhoff extracts (formerly Regeneresen) very successfully. Since the RNA extracts have a higher concentration of the active ingredient than the previous Regeneresen, an average of 3-5 vials was used with 250ml of physiological saline solution for each infusion. This is how my successor in the practice works too.

The concept of the treatment is summarised in the following table:

	Application	Dose	Notes
Regeneresen	intramuscular	2 ampoules / session; 2 - 3 sessions / week	Total amount 20-40 ampoules
	intravenous infusion	5 - 7 ampoules in 250ml of physiological saline solution; 1 - 2 infusions / week	Total amount 30-50 ampoules
Dyckerhoff extracts	intramuscular	2 vials / session; 2 - 3 sessions / week	Total amount 12-24 vials
	intravenous infusion	3 - 5 vials in 250ml of physiological saline solution; 1 - 2 infusions / week	Total amount 18-30 vials

The case study shown in the following part was carried out with Regeneresen. The higher concentration recipes of Dyckerhoff extracts are currently available for the relevant treatments. Dyckerhoff Pharma provides information on this.

Here are some selected cases from my own practice over the period from 1994 to 2010

Initially, I wrote down a concept which I had developed and which had been proven in my practice.

Naturopathy treatment concept to restore or maintain wellbeing

1. Injection series with Regeneresen manufactured by Dyckerhoff Pharma
10-20 injections 2-3 x per week (1-2 x per year), intragluteal, preferably with the preparations RN 13, cerebral hemispheres, Osteochondrin S and with the relevant indication of Regeneresen in other selected organs.
2. Infusion therapy with neurotropan manufactured by Phönix
10 infusions 2-3 x per week (1-2 x per year)
3. Complex homeopathy with
Potassium dichromate Phcp ("vision"),
Gelsemium Phcp ("Hearing"),
Aurum iodatum Phcp ("Understanding"),
3 x 15 globules alternating every three days over a period of three months of the year or as a long-term therapy.

I only used hormone therapy (DHEA, melatonin, testosterone and other "lifestyle drugs") in very rare cases where there was clear evidence of a deficiency. I am of the opinion that we should only intervene in the physiology of the human body to activate, regenerate and maintain it. A substitution should therefore only be made if an organ is no longer working at all, cannot be regenerated or has been removed (e.g. following a total hysterectomy or strumectomy).

This concept was keenly embraced by my patients with typical symptoms of old age, a decrease in performance or a loss of performance and strength, joint and spinal problems, decreased memory, hormonal disorders and the like, as conventional medical alternatives often fail.

Table 1: Overview of the case studies shown below

Patient	Diagnosis
Case 1	Depressive crises; cardiomyopathy, ventricular fibrillation
Case 2	Pseudomyxoma peritonei
Case 3	Spinal syndrome; depressive episodes
Case 4	Rheumatoid polyarthritis; degenerative changes to the spine; gonarthrosis; structural foot problems; diabetes mellitus, obesity; arterial hypertension; heart attack
Case 5	primary hyperparathyroidism; osteoporosis; arthrosis of the shoulder; spondylarthrosis of all sections of the spine
Case 6	Fibromyalgia; spinal syndrome; slipped disc L4/L5; liver metabolism disorder; labile hypertension
Case 7	Cerebral circulation disorder; disorder of fat metabolism; osteoporosis; depressive syndrome; polyarthrosis; spondylarthrosis, facial dermatosis; moderate varicose veins
Case 8	Pilocytic astrocytoma (astrocytes of various degrees of severity) in the left lateral ventricle and fourth ventricle
Case 9	Cardiomyopathy; arterial hypertension; diabetes mellitus; spinal syndrome; spondylarthrosis; diabetic retinopathy; herpes zoster thoracis; postherpetic neuralgia
Case 10	Thyroid function disorder; poor performance; hormone disorders
Case 11	Toxic liver damage; severe hepatic coma with massive ascites
Case 12	Major subretinal choroid bleeding with a total loss of vision; early macular degeneration on both sides
Case 13	Recurrent neuritis of the optic nerve
Case 14	Chronic, recurrent bronchitis
Case 15	Recurrent bronchopneumonia and sinusitis; genetic IgA-AK deficiency syndrome
Case 16	Ablatio retinae; macular degeneration; status post cataract operations
Case 17	Labile hypertension; apoplexy with paralysis of the left leg and weakness in the right leg
Case 18	Moderate sensorineural hearing loss on both sides
Case 19	Inhibition of maturation of the forebrain, status post bronchial asthma; allergic dermatosis
Case 20	Blockage of the sacroiliac joint; hypogonadism
Case 21	Colitis as a result of radiation therapy for a prostate carcinoma
Case 22	Hypertensive hear disease; first degree AV block; diabetes mellitus with chronic renal insufficiency and diabetic retinopathy; psychomotor function slowed (cerebral circulation disorder)

Case 1:

K., C.-P., born 1925, male, retired dentist

Diagnoses:

- **Status post severe depressive crises** (unresolved professional history, family problems)
- **Severe cardiomyopathy**
- **Status post ventricular fibrillation (given Marcumar)**
- **Status post mild apoplectic insult**

The patient received from me over the period from 2005 a series of infusions of neurotropan manufactured by PHÖNIX to treat his depression.

My successor is now using the preparation choline citrate which is now available from the Arnika pharmacy in Munich (active ingredient of neurotropan which is no longer available), also with high levels of success.

As a prominent dentist in Munich, the patient used to have contact with Dyckerhoff and had even used Regeneresen on his own patients, for example in jaw necrosis or temporomandibular joint arthrosis. This is why he was particularly willing to allow Regeneresen therapy on himself.

REGENERESEN therapy (infusions) since 2008:

- 5 amp. Diencephalon
- 5 amp. Basal ganglia
- 5 amp. Artery
- 3 amp. Medulla oblongata
- 5 amp. Heart
- 5 amp. Cerebral hemispheres
- 5 amp. Cerebellum
- 5 amp. Midbrain
- 10 amp. RN13

Two treatments following the same schedule in each of 2009, 2010 and 2011.

The infusions were carried out once a week with 250ml of physiological saline solution with administration of 7-8 ampoules of Regeneresen in each case.

The infusions were tolerated without any problems and led to a considerable stabilisation of the state of health.

Case 2:

Pat O., D., born 1936, male, master electrician

Diagnoses:

- **Pseudomyxoma peritonei** which was removed in an operation and treated with chemotherapy 15 years ago. A current CT showed a mass which may have been a tumour on the hilum of the liver.
- **There was considerable kidney damage as a result of the toxic effect of the chemotherapy. Iron deficiency anaemia with a considerable reduction in general health**
- **Immunodeficiency**

The patient has been living in fear of cancer for many years, and at the start of my treatment in January 2010 had suffered significant physical changes.

Nobody had managed to free him from this worry before this. There was also no possible causal therapy. The patient had been prepared for possible haemodialysis. Since the blood values were really poor, injections of the iron preparation were only administered once a week.

Treatment from January 2010: infusion therapy 2 x per week (total of 10 infusions) with Pascorbin (manufactured by Pascoe) with the addition of various complex homeopathic agents manufactured by Heel, Hevert and PHÖNIX, in addition to 3,000 micrograms of vitamin B12.

Regeneresen injections were then carried out in February/March and September/October 2010 in accordance with the following schedule:

- 10 amp. RN13
- 10 amp. Kidneys
- 10 amp. Bone marrow

It was astounding how the blood values improved overall in a very short time and even normalised (Hb, erythrocytes and creatinine), and general wellbeing also improved.

Follow-up examinations by the specialists also showed a completely stable results. The swelling on the hilum of the liver had not grown.

My successor continued this successful treatment.

The patient, with whom I am still in contact at his request, has a high optimism for the future once again, which his whole family are also very pleased about (his wife had said that he was very depressed and was preparing for his death).

Since then (March 2012), he has successfully completed a total endoprosthesis of the right hip.

Case 3:

G.-Sch., H., born 1934, female, retired

Diagnoses

- **Chronic, recurrent spinal syndrome** with occasional serious pain and considerable limitations of movement
- **Discrete degenerative changes to the spine and the sacroiliac joint**
- **Tendency to depressive episodes**

In 2006, 2007 and 2008, the patient received Regeneresen injections in accordance with the following schedule, with 3 x 2 ampoules a week in each case:

- 5 amp. RN13
- 5 amp. Osteochondrin S
- 5 amp. Connective tissue
- 5 amp. Thymus

The patient has been doing well since 2008. Acute pain syndromes no longer occur.

She is essentially more mobile and can now do more sport again (running, gymnastics, cross-country skiing).

Case 4:

K., L., born 1938, male, baker (retired)

Diagnoses:

- **Rheumatoid polyarthritis**
- **Severe degenerative changes to the spine**
- **Gonarthrosis on both sides**
- **Considerable static foot problems**
- **Type 2 diabetes mellitus, severely overweight**
- **Arterial hypertension**
- **Status post heart attack**

A large number of doctors of conventional medicine, including orthopaedic surgeons and rheumatologists, had used their entire range of diagnostics skills on the patient.

Other than cortisone in a range of forms and the usual painkillers and physiotherapy and massages, however, no other treatment was used. There was no improvement in the diverse clinical picture.

Regeneresen injections 2003:

- 10 amp. Osteochondrin S
- 5 amp. RN 13
- 5 amp. Muscles
- 2 amp. Pancreas
- 1 amp. Adrenal cortex

Result: considerable improvement in the general condition

Regeneresen injection 2004 (January/February)

- 10 amp. Osteochondrin S
- 5 amp. RN 13
- 5 amp. Muscles
- 5 amp. Intervertebral disc

Regeneresen injection 2004 (August/September)

as above, but with RN 13 replaced by connective tissue

Regeneresen injections August 2005

- 10 amp. Osteochondrin S
- 5 amp. RN 13
- 5 amp. Connective tissue
- 5 amp. Muscles
- 5 amp. Pancreas
- 5 amp. Intervertebral disc

The patient had not anticipated the positive results of treatment.

As rheumatoid polyarthritis occurred again in 2009 which had to be treated with cortisone, Regeneresen were administered again in February/March 2010 in accordance with the above schedule. In 2011 Mr. K suffered sudden cardiac death.

Case 5:

K., M. born: 1927, female, retired

Diagnoses:

- **Primary hyperparathyroidism** (confirmed by chemical tests carried out in the laboratory and with a sonograph)
- **Advanced osteoporosis**
- **Severe arthrosis of the shoulder joint on both sides**
- **Considerable spondylarthrosis of all sections of the spine**

Operation on 29 May 2008: revision of the epithelial body with removal of an adenoma of the right parathyroid gland.

Medication: Frubias calcium drinking ampoule as required

Regeneresen therapy (from 18 June 2008):

- 10 amp. Osteochondrin S
- 10 amp. Intervertebral disc
- 10 amp. Osteoblasts
- 10 amp. RN 13
- 5 amp. Placenta fem.
- 5 amp. Thyroid gland

distributed over 8 x 1 infusion / week

Due to the administration of Marcumar and the fact that the patient was very thin, the treatment was not intramuscular but was administered as an infusion.

Result:

The infusions were tolerated very well and were therefore repeated in 2009. The general state and the pains in the musculoskeletal system improved considerably. To this day, no medication is required to treat this. Her husband, who required care, died in 2009, so the physical strain she had been bearing up until that point was removed.

Case 6:

SCH., H., born 1951, male, teacher

Diagnoses:

- **"Fibromyalgia"**
- **Chronic, recurrent spinal syndrome**
- **Status post slipped disc L4/L5 (conservative therapy)**
- **Liver metabolism disorder with a considerable increase in the gamma-GT**
- **Labile hypertension**

At the start of our treatment in 1997, the patient had been "over treated" with physiotherapy.

He had even been told not to do regular physical activity!

This meant that the initial therapy was difficult to design, but over time and with targeted psychological consultation, targeted medication and infusion therapy, a reduction of the constant massages and physiotherapy and last but not least targeted Regeneresen injections, he experienced a considerable improvement in his general state.

The Regeneresen series were carried out in 2003, 2005, 2007 and 2009.

The following were used:

- 10 amp. RN 13
- 10 amp. Muscles
- 10 amp. Liver

Since the liver values had not improved and hepatitis could not be ruled out, I had to recommend that the patient reduce his alcohol consumption and motivate him to carry out more active exercise therapy with the help of his sporty wife.

In addition to this, he was administered medical treatment including with:

- Zinc, magnesium
- Hepar POS and Cefasilymarin 140
- Harpagoforte 375 mg

Result: the general condition is still very good. The patient hardly has any remaining symptoms, and even his metabolism has improved. Mr. Sch is able to function in both a professional and private capacity.

Case 7:

M., I., born 1926, female, retired

Diagnoses:

- **Cerebral circulation disorder**
- **Fat metabolism disorder (liver, pancreas)**
- **Osteoporosis**
- **Recurrent depressive syndrome**
- **Polyarthrosis**
- **Severe spondylarthrosis**
- **Recurrent facial dermatosis**
- **Moderate varicose veins**

The patient had been successfully treated with naturopathic methods since 1999, e.g. regular detoxification with the detox concept created by PHÖNIX, colonic irrigation therapy, infusion treatments with neurotropan, homeopathic vein therapy, balances orthomolecular treatment, treatment of the polyarthrosis with Harpagoforte 375 mg and other treatments.

The patient lived alone and was therefore very grateful for an improved quality of life.

I carried out the first injections with Regeneresen to stabilise the patient in November 2003.

The following were used:

- 10 amp. RN 13
- 4 amp. Liver
- 4 amp. Cerebral hemispheres
- 3 amp. Diencephalon
- 2 amp. Skin

Result:

According to the patient, this treatment was "the icing on the cake". Afterwards she was very well.

In May 2004 she has the next Regeneresen treatment.

The patient had very concrete ideas about this. She wanted something for the inner ear, the eyes, the skin, fat metabolism and general wellbeing.

The following were used:

- 5 amp. RN 13
- 3 amp. Skin
- 3 amp. Liver
- 3 amp. Pancreas
- 3 amp. Basal ganglia
- 3 amp. Diencephalon
- 2 amp. Thyroid gland

Further treatments were carried out in November/December 2004 and March/April 2005.

The following were used:

- 10 amp. RN 13
- 5 amp. AU 4
- 5 amp. Skin
- 5 amp. Retina
- 3 amp. Cerebral hemispheres
- 3 amp. Thyroid gland

In the intervening period, a cataract operation had been carried out on both sides and macular degeneration had been identified. She also wanted me to give her something for her diminishing hearing,

so in November/December 2005 I used the following:

- 8 amp. RN 13
- 5 amp. AU 4
- 5 amp. Cerebral hemispheres
- 4 amp. Skin
- 4 amp. Retina
- 4 amp. Thyroid gland

Spring and autumn injection series 2006/2007 and 2008:

- 10 amp. RN 13
- 10 amp. Skin
- 5 amp. AU 4
- 5 amp. Cerebral hemispheres
- 5 amp. Retina
- 5 amp. Thyroid gland

Overall assessment:

Until she moved away, her general condition was excellent for her age. The ocular focus findings remained stable and did not get any worse. The bone density measurement taken in April 2006 even showed an increase in bone density.

The patient found it incredible that she felt so well at the age of 83. She has been living in managed apartments in Heidelberg near to her children since 2009.

Case 8:

T., M., born 1987, male, student

Diagnoses:

- **Pilocytic astrocytoma** (astrocytes of various degrees of severity) in the left lateral ventricle and fourth ventricle (first diagnosis in September 2005)
- **Subtotal tumour resection** 9 September 2005
- Fall on 15 September 2005 with **subdural haematoma on both sides of the hemisphere**, relief through **trepanations**
- **Posttraumatic hemiparesis of the right hand side**
- **Peripheral facial paresis**
- **Intercurrent hypopituitarism** (hypofunction of the anterior pituitary gland)
- **One-off convulsive seizure** 20 September 2005
- **Hydrocephalus**
- **VP shunt (ventriculo-peritoneal)**

The most significant symptoms

- Considerable disorder of both the gross and fine motor skills
- Balance disorders, so sits in a wheelchair most of the time
- Severe ataxia
- Increased movement of the eyes with incomplete closure of the eyelids and decreased eyelid impact
- Considerable speech disorder as a result of the facial paresis
- Posture sunk down within the body (significant hunchback, hardly possible for him to look straight ahead)

Regeneresen therapy from June 2008 provided by the GP in accordance with a programme I developed:

- 10 amp. RN 13
- 5 amp. Midbrain
- 5 amp. Cerebellum
- 5 amp. Diencephalon
- 5 amp. Medulla oblongata
- 5 amp. Spinal cord
- 5 amp. Muscles

In parallel, 2-3 x per week neurotrophin infusions (3 amp. in 250ml NaCl). The treatment was very well tolerated.

Six weeks after completion of the treatment there was an overall improvement, particularly in the in some cases considerable ataxia

Follow-up treatment with 4 amp./week intramuscular: May-July 2009

Results on 26 July 2009:

- Considerable improvement in ataxia; is able to lift a cup to his mouth independently
- Walking with a walker or being guided by the arm improved considerably
"Now we can go anywhere"
- Speech, posture and lid closure all improved considerably
- Hair growth improved
- Subjective improvement in the ability to hear in his right ear

In 2009 he started training in office work at the vocational training centre in Neckargmünd with the aim of becoming an office administrator

In 2010, a further Regeneresen treatment was carried out at the patient's request in order to achieve a further stabilisation of the overall result.

In addition to the treatment with Regeneresen:

Manual therapy and myoreflex therapy

- 3 x weekly strength exercises
- Daily bicycle ergometer
- Walks outside every day

Despite the disorder of accommodation, works on a PC and is an active and optimistic individual.

Case 9: *This patient is one of the first that I treated with Regeneresen.*

B., B. born: 1921, female, retired

Diagnoses:

- **Severe cardiomyopathy** with two successful cardioversions (Cordarex ½ tablet daily, Marcumar in accordance with INR)
- **Arterial hypertension**
- **Type 2 diabetes mellitus**
- **Chronic spinal syndrome with advanced spondylarthrosis**
- **Diabetic retinopathy**
- **Status post severe herpes zoster thoracis in 2003 with postherpetic neuralgia** of changing intensity

Treatment:

This patient received 2 x 5 infusions with Regeneresen (1 x per week) each year from 1997 to 2004

- 3 amp. RN 13
- 2 amp. Retina
- 2 amp. Heart
- 2 amp. Muscles
- 1 amp. Choroid membrane

(in each case in 250ml physiological saline solution)

I treated the postherpetic neuralgia with regular IV injections (B12, traumeel, antineuralgic injections, Cuprum injektipas, alternatively also Vertigoheel and Solidago complex)

From 2005, no further Regeneresen treatment were carried out as her husband who had also been a "Regeneresen patient" with me died at 90 (still mentally agile!) and the patient no longer had the resources to pay for it.

She has since also survived a fracture of the patella and an operation on this and a left mammary amputation for an encapsulated carcinoma in February 2009. Due to bleeding in the left eye with almost complete loss of vision, the Marcumar was stopped with the agreement of the specialist in internal medicine with no negative consequences for the cardiomyopathy.

In 2010 the patient did not suffer from any diseases of note. In November 2011 she died of an embolism in the brain shortly after her 90th birthday following a fall in her home.

Case 10:

SCH., A., born 20 March 1949, female, domestic aid

Diagnoses:

- **Thyroid gland functional disorder**
- **Poor performance**
- **Hormonal disorders**

Initial therapy with Regeneresen in 2004:

- 9 amp. RN 13
- 6 amp. Thyroid gland
- 5 amp. Thymus

Conclusion two months later:

"I feel better than I have in ten years!"

Further Regeneresen injections were carried out on the basis of the same schedule in 2005, 2006, 2008 and 2009. The schedule was only enhanced by the addition of 5 amp. of Osteochondrin S.

The patient's condition continues to be stable.

Case 11:

M., K. - H., born 1939, male, pensioner

Diagnosis (1998):

- **Occupational toxic liver damage**(solvents used incorrectly in a metal processing factory)
- **Severe hepatic coma with massive ascites**

Treatment:

- stopping the life-threatening acute stage
- preparing for a liver transplant
- vitamin C infusions and thymus injections.

In addition to this, considerable improvement in general wellbeing

Additional treatment measures:

- liver transplant 5 May 1999
- two weeks beforehand the patient had two Regeneresen infusions with an interval of five days

Per infusion:

- 5 amp. Liver
- 3 amp. RN13
- 1 amp. Connective tissue
- 1 amp. Kidneys.

Result:

The patient survived the transplant excellently.

- Later consequences:

Severe organic brain syndrome as a result of the liver coma with toxic brain damage.

Treatment:

- Large amounts of psychotropic drugs
- Regeneresen therapy (11 June, 18 June, 25 June and 2 July 2003)

each infusion with

- 4 amp. Cerebral hemispheres
- 3 amp. RN13

Result:

The infusions were again well tolerated.

The patient was well until 2011. He even started working from home for his former company.

Unfortunately the patient died in 2012 as a result of a dramatic worsening of the organic brain syndrome.

Case 12:

K., A., born 1936, male, retired

Diagnoses:

- **Major subretinal choroid bleeding with a total loss of vision; early macular degeneration on both sides (November 2007)**
- **Early macular degeneration on both sides**
- **Treatment with Marcumar for 10 years for recurrent atrial fibrillation**

Retrobulbar injections were avoided due to the Marcumar.

Treatment:

A total of 17 infusions with Regeneresen in 2008 and 2009.

Per infusion with 250ml physiological saline solution:

- 2 amp. Retina
- 1 amp. Optic nerve
- 1 amp. Choroid membrane
- 2 amp. Heart
- 2 amp. Cerebral hemispheres, alternating with RN13
- Regeneresen Liver intermittently to improve the metabolism.

Results in 2010

The patient is in excellent physical and mental condition.

Ophthalmological results from January 2010 and March 2012: improvement in visual acuity in the left eye by 120% and considerable improvement in the right eye.

The patient stated that he could see outlines again.

Both he and his ophthalmologist were very happy with this positive development and Mr. K continued the Regeneresen therapy in 2010 and 2011.

Case 13:

G., A., born 1971, female, administrative workers

Diagnoses:

- **Recurrent neuritis of the optic nerve with clear progression.**

The patient was sent to me in 2003 by an ophthalmologist in Freudenstadt because all of the conventional treatments had failed including high dose treatment with cortisone in Freiburg university hospital.

- **Dwarfism**

Additional finding in the head-CT which had not been taken into account in treatment to date:

- **Chronic sinusitis of the left maxillary sinus.**

I was initially able to treat this as a trigger for the development of the interference field which was causing the inflammation of the tendons with homeopathic agents and vitamin C infusions.

Subsequent to this, I carried out Regeneresen therapy in accordance with the following schedule:

- 10 amp. RN 13
- 8 amp. Optic nerve
- 4 amp. Retina
- 2 amp. Choroid membrane

This treatment was repeated in 2004 in the patient's home.

The disease is completely healed. The patient is now married and has had two children.

Before I continue to further patients, I have added a section about thymus therapy with REGENERESSEN, which cases 14 and 15 refer to in particular.

Why thymus injections?

Their aim is to counteract decreasing activity of the thymus gland.

The following have a lack of thymus peptides:

- Everyone over the age of 45 (thymus injections also stimulate the metabolism)
- Patients with poor performance
- Patients with chronic recurrent infections
- Patients with autoimmune diseases (e.g. rheumatism)
- Patients with neurodermatitis
- Patients with intestinal dysbiosis
- Patients who are terminally ill
- Patients following radiation therapy or chemotherapy (also to reduce the side effects and achieve a considerable improvement in the immune status)
- Patients undergoing long-term treatment with cortisone, antirheumatic drugs, immune suppressants etc.

The duration of treatment depends on the disease in question and its severity. In initial and intensive therapy, 2-3 injections are generally given intragluteally over 3-4 weeks with 1-2 thymus vials / week.

Case 14:

M., O., born 1934, female, retired

Diagnosis:

- **Chronic recurrent bronchitis for 40 years**

Initial consultation on 5 June 2008, suggested treatment: thymus injections with Regeneresen

Treatment in June 2008:

The patient was injected with 10 amp. of thymus Regeneresen intragluteally, with 2 x 2 amp. per week

Conclusion after one year:

"I haven't suffered with anything for a year! I even survived a total endoprosthesis of the left hip without infection."

The second injection series requested by the patient was carried out in June 2009, and a further series was administered in August 2010.

Case 15:

H., M. born 1966, male, stonemason (self-employed)

Diagnoses:

- **Recurrent bronchopneumonia and sinusitis treated with large amounts of antibiotics**
- **This resulted in a significantly weakened immune system**
- **Genetic IgA-AK deficiency syndrome with decreased IgG-2 and IgG-4 levels**

The patient is frequently unable to work because of his health.

Treatment:

Regeneresen treatment with thymus each September since 2004: 2 amp. 3 x per week of intramuscular thymus, always with a total of 10 ampoules.

Results following treatment:

- Stabilisation of the physical condition
- Treatment with antibiotics no longer necessary

I treated mild infections with the homeopathic "flu cocktails" that my patient was aware of and liked the use of, with the addition of vitamin C.

Case 16:

G., B., born 1950, female, housewife/waitress

Diagnoses:

- **Status post ablatio retinae**, treated with several laser procedures and oil drops (silicone oil)
- **Macular degeneration**
- **Cataract operation**

The right eye was affected. The treatment was carried out at Tübingen university hospital.

A Regeneresen therapy was carried out in my practice immediately after the cataract operation at the patient's request (November/December 2005)

The following were used:

- 10 amp. Retina
- 5 amp. RN 13
- 5 amp. Choroid membrane
- 5 amp. Optic nerve

Additional Regeneresen treatments followed in July 2006 and spring 2007.

The following were used on these occasions:

- 6 amp. Retina
- 3 amp. Choroid membrane
- 3 amp. Optic nerve

In contrast to the predictions by Tübingen university hospital and the attending ophthalmologist, there was a full remission of the disease.

The patient no longer suffered from any problems, either subjectively or in terms of visual performance.

Case 17:

Pat F., P., born 1936, male, chef

Diagnoses:

- **Labile hypertension**
- **2004 apoplexy with paralysis of the left leg and weakness in the right leg**

Rehabilitative after-treatment and subsequent physiotherapy failed to heal the patient.

He was suffering from weakness in his legs. "It's not like it used to be, I can't ski any more. I can still do golf just fine".

From May to June 2006, the patient was treated with an infusion therapy of vitamin C and neurotropan with good success in terms of the previous constant dizziness and the physical performance.

In July and November/December I carried out two series of Regeneresen injections

The following were used:

- 10 amp. Cerebral hemispheres
- 5 amp. RN 13
- 5 amp. Artery
- 5 amp. Diencephalon
- 3 amp. Hypophysis masc.
- 2 amp. Basal ganglia

There was a considerable improvement in the neurological deficits and general wellbeing.

The patient repeated the Regeneresen treatment in 2007.

Case 18:

P., Pascal, born 1989 and P., Manuel, born 1991, both male, students

Diagnoses:

In 2002, the two brothers were diagnosed with

- **moderate sensorineural hearing loss on both sides.**

The specialist's recommendation: provision of a hearing aid; treatment not possible.

In November/December 2002 I carried out Regeneresen therapy on the two boys with the special preparation AU 4.

In each case, 8 injections of 2 amp. AU 4 were administered

Homeopathic adjuvant therapy: Gelsemium Phcp 3 x 10 globules daily

Six weeks after the end of treatment, there was a significant improvement in the subjective auditory sensation. The boys had no problems with their hearing at school or at home.

They did not have to use hearing aids.

Further Regeneresen series were carried out in May/June 2003, April 2004, May 2005 and September 2008.

The damage to the hearing had not progressed by 2009.

The subjective auditory sensation continued to be very good.

The provision of hearing aids was not necessary until 2009.

Case 19:

M., M., born 1984, male

Diagnoses:

- **Inhibition of maturation of the forebrain**, probably as a result of insufficient blood supply to the forebrain in the last weeks of pregnancy and during birth (caesarean section)
- **Bronchial asthma since the age of 3**
- **Allergic dermatosis since the age of 8**

At the start of our therapy, the asthma and the allergy had been cured by rigorous treatment administered by an experienced homeopathic practitioner.

The following disorders were present at the start of our treatment:

- Speech disorder
- Disorder of the speech and physical motor functions
- Complete dyslexia
- Drive disorder

The damage meant that M. had to attend a school for the disabled.

Only the speech disorder had been improved through targeted speech therapy.

The initial treatment provided by us was in the second half of 1996, the second treatment series started on 3 February 1997. The treatments were carried out 2-3 times per week.

Treatment plan:

Fifteen intragluteal Regeneresen injections in accordance with the following schedule (summarised):

- 15 amp. Cerebral hemispheres
- 3 amp. Pineal body
- 3 amp. Hypophysis
- 3 amp. Hypothalamus
- 3 amp. Adrenal cortex
- 3 amp. Thyroid gland

Fifteen infusions with the medication neurotropan manufactured by Phönix (in each case 3 and then later 4 ampoules in 250ml physiological NaCl solution with an infusion duration of 45 minutes).

Fifteen treatments with the magnetic field in combination with ionised medical oxygen.

All treatments were synchronously in the order injection, infusion and magnetic field/oxygen.

Since all of the attempts to treat the patient using conventional methods had failed to date, the treatment concept was supported by the GP and fully financed by the health insurance provider AOK.

Just a short time after the start of treatment, the parents and I as the person administering the treatment noticed a real leap in both the physical and mental development of the boy, who was 12 at the time.

The drive disorder disappeared completely.

The boy was better motivated both in the special school and at home with his parents, he was interested in more and had recently become more active and mobile.

The special school said that M. was helpful, willing to learn, persistent, kind, calm and never quarrelsome or aggressive.

The male sexual characteristics were considerably more pronounced. While in nursery M. had only really been interested in dolls and girls' clothing, he was suddenly interested in handicrafts, making things and cooking.

He even enjoyed learning to do simple tasks on the computer.

His speech and physical motor skills have improved significantly.

We carried out this treatment concept once or twice a year until the boy was 18, in the later years with just

- 10 amp. RN 13
- 10 amp. Cerebral hemispheres
- 4 amp. Thymus

The treatment stopped in May 2002.

The declared aim was to bring M. to a state of economic independence and the ability to learn a professional skill under assisted conditions.

This was achieved to the full extent.

Fortunately, the relevant health authority took on the full costs of the treatment on this premise until the treatment was complete.

Case 20:

B., R. born 1993, male, student

Patient history:

Treated for a blockage of the sacroiliac joint in July 2006

Hypogonadism with the corresponding external appearance

Family: type 1 diabetes mellitus in the older brother

Laboratory results (July 2006):

Fasting blood glucose 107 mg/dl

Thyroid gland values were also normal

Total testosterone 83.1 ng/dl (normal range: 400 to 1200)

Diagnosis (January 2007):

- **Acute type 1 diabetes mellitus** , occurring following an infection
- Klinefelter syndrome was ruled out with cytogenetic tests.

Treatment: insulin since January 2007

Regeneresen injection treatment in June/July 2007

- 5 amp. RN 13
- 5 amp. Pancreas
- 5 amp. Testes
- 5 amp. Adrenal cortex
- 5 amp. Hypophysis masc.
- 5 amp. Placenta masc.
- 1 amp. Hypothalamus (3 x 2 amp./week intramuscular)

Results following treatment:

R. is doing very well. He is developing completely normally both physically and mentally. Total testosterone six weeks after Regeneresen therapy: 518 ng/dl

Case 21:

Patient J., V., born 1941, male, insurance salesman

Diagnosis:

- **Chronic, treatment-resistant colitis as a result of radiation therapy for a prostate carcinoma**

The initial diagnosis of prostate carcinoma (confirmed using a punch biopsy) was made in April 2002. Percutaneous radiation of the prostate and the lesser pelvis was carried out from May to July 2002. Immediately after completion of the radiation therapy, I carried out an infusion treatment with a high dose of vitamin C manufactured by Pascoe (in each case 7.5g in 250ml of physiological NaCl solution) with the addition of further anti-inflammatory, detoxifying and mucous membrane-protecting complex agents manufactured by Heel (Mucosa comp., Traumeel, Engystol, Hepar comp., Solidago comp. und Galium Heel). Alternating with vitamin C the patient received infusions with neurotropan manufactured by Phönix.

In total, 12 infusions were carried out over a period of six weeks and were then repeated at intervals of four weeks.

The patient did not continue conventional treatment, with the exception of taking alna 0.4 (1 x 1 tablet/day).

The patient merely had uro-oncological checked every three months (sonography, PSA levels).

The patient recovered very quickly, both physically and psychologically, and experienced total remission of the tumour. The PSA levels and the clinical results were completely normal by the end of 2006.

There was then an increase in PSA level to 6ng/ml with no clinical symptoms and no other indications of renewed tumour growth.

Unfortunately, as a result of the radiation therapy highly irritating and treatment-resistant colitis developed with severe tenesmus and explosive bowel movements.

All of the medications proven for these results and this clinical picture were used, with no success. Since as a freelance insurance salesman the patient frequently had to work in the field, the continual urge to defecate could only be contained by him continually taking Imodium.

Due to the good experiences with Regeneresen, I decide to carry out an injection treatment on the basis of the following schedule:

- 20 amp. RN 13
- 10 amp. Large intestine
- 5 amp. Connective tissue
- 3 amp. Vascular wall

Treatment period: 10 January to 21 January 2005.

The injections were carried out three times per week, with 2 amp. of Regeneresen administered intragluteally in each case.

Conclusion:

Six weeks after the end of the Regeneresen therapy, there was a significant improvement. The patient showed absolutely no symptoms for months and stated that the result of treatment was "sensational".

We repeated the same treatment in November/December 2005 and August 2006.

Case 22:

Patient G., W. born: 27 July 1940, male

Diagnoses:

- **Advanced hypertensive heart disease**
- **First degree AV block**
- **Diabetes mellitus with chronic renal insufficiency and diabetic retinopathy** (early retirement in 1993)
- **Slowing of the psychomotor functions (cerebral circulation disorder)**

Results on 25 June 2007:

Creatinine 4.76mg/dl

Treatment:

Regeneresen treatment from 2 July 2007 to 2 August 2007: (twice a week with 4 amp. Regeneresen in each case)

- 10 amp. Kidneys
- 5 amp. Heart
- 5 amp. RN13
- 5 amp. Cerebral hemispheres
- 5 amp. Retina
- 4 amp. Liver
- 3 amp. Pancreas
- 3 amp. Thyroid gland

Results following treatment:

Appointment on 19 September 2007: general wellbeing very good

Results on 11 September 2007 (GP): creatinine 2.96mg/dl

The next treatment was carried out in accordance with the same schedule in November/December 2007 and in March/April 2008.

I think it is also important to mention that there are cases in which we are unable to help. Following the urgent appeal of the parents, I treated two children with a hereditary muscular disease (Friedreich's ataxia), with no improvement. Success is also doubtful in tinnitus from which the patient has been suffering for many years (as with all other treatments for tinnitus).

At the end of my report on my experiences, I would like to thank Dr. Georg Stommel and the entire team at Dyckerhoff for their many years of excellent collaboration and their always competent technical advice. I was always able to send treatment requests in writing, by post, by fax (0221-95743745) or via email (dyckerhoff@dyckerhoff-pharma.de; www.dyckerhoff-pharma.de) to Dyckerhoff or to make them on the telephone (0800-8480840). The wellbeing of the patient who had been entrusted to us was always the focus with this.

The treatments are now carried out with recipes made of Dyckerhoff extracts. They are manufactured from the original active ingredients produced by Dyckerhoff (Dyckerhoff extracts), from which prescription drugs are made in some German pharmacies. You can get more information on this from Dyckerhoff Pharma.

I wish my readers all the best in the treatment of their own patients.

My treatment experiences are only to be viewed as such. They are no guarantee that the same results can be achieved in my readers' patients, because each patient is different and the therapist must always develop an individual treatment.

I therefore always avoided going into too much detail about adjuvant therapies with many of my patients. What I never did was to stop proven therapies given by other doctors or homeopathic practitioners before my treatment. I also used existing laboratory results and other examination methods to avoid carrying out the same examinations again.

Overview of individual diagnoses with the allocation to the case studies

Indication	Case report	Page
Ablatio Retinae	Case 16	35
Apoplexy	Case 17	36
Astrocytoma	Case 8	24
AV block	Case 22	43
Slipped disc	Case 6	20
Bronchopneumonia	Case 15	34
Disorder of cerebral circulation	Cases 7 and 22	21 and 43
Chronic bronchitis	Case 14	34
Depression	Cases 1, 3 and 7	14, 16 and 21
Dermatosis	Case 7	21
Type 2 diabetes mellitus	Cases 4, 9 and 22	17, 27 and 43
Fat metabolism disorder	Case 7	21
Fibromyalgia	Case 6	20
Gonarthrosis	Case 4	17
Hepatosi	Cases 6 and 11	20 and 29
Herpes zoster	Case 9	27
Heart attack	Case 4	17
Hormonal disorders	Cases 10 and 20	28 and 41
Hyperparathyroidism	Case 5	19
Hypertension	Cases 4, 6, 9, 17 and 22	17, 20, 27 and 36
Hypogonadism	Case 20	41
IgA-AK deficiency syndrome	Case 15	34
Cardiomyopathy	Cases 1, 9 and 22	14, 27 and 43
Colitis	Case 21	42
Liver damage, hepatic coma	Case 11	29
Liver metabolism disorder	Case 6	20
Poor performance	Case 10	28
Macular degeneration	Cases 12 and 16	30 and 35
Optic nerve neuritis	Case 13	32
Renal insufficiency	Case 22	43
Osteoporosis	Cases 5 and 7	19 and 21
Polyarthritis	Case 4	17
Polyarthrosis	Case 7	21
Postherpetic neuralgia	Case 9	27
Pseudomyxoma peritonei	Case 2	15
Inhibition of maturation in the forebrain	Case 19	38
Diabetic retinopathy	Cases 9 and 22	27 and 43
Thyroid gland functional disorder	Case 10	28
Shoulder joint arthrosis	Case 5	19
Hardness of hearing	Case 18	37
Sinusitis	Case 15	34
Spondylarthrosis	Cases 5, 7 and 9	19, 21 and 27
Subretinal choroidal haemorrhage	Case 12	30
Thymus treatment	Cases 14 and 15	34
Varicosi	Case 7	21
Spinal syndrome	Cases 3, 4, 6 and 9	16, 17, 20 and 27

